

“Clinical use of QuiremScout® in a 55-year-old male patient with hepatocellular carcinoma (HCC)”

AUTHORS: Dr. S. Grosche-Schlee (NM), Dr. C. Radosa (IR), Prof. J. Kotzerke (NM), Prof. R.-T.-Hoffmann (IR), University Hospital Dresden, Germany.

PATIENT CLINICAL INFORMATION

55-year-old male patient with HCC and untreated so far (**Fig.1**). The patient was in a slightly reduced general condition (EGOG 1). Laboratory chemistry showed thrombocytopenia and low liver enzymes. Therefore, SIRT was approved in the multidisciplinary tumor board.

SIRT WORK-UP

Evaluation with ^{99m}Tc-MAA

The work-up for SIRT was initially done by means of angiography and ^{99m}Tc-MAA-administration. The ^{99m}Tc-MAA-SPECT/CT showed significantly increased accumulation in the known HCC manifestations (**Fig.2**), but also a dystopic extrahepatic activity accumulation in the gallbladder was seen.

Evaluation with QuiremScout®

For risk assessment of a potential radiogenic cholecystitis, it was decided to use QuiremScout®. QuiremScout® was injected in both liver lobes with activities of 188 and 89 MBq analogous to the ^{99m}Tc-MAA procedure. The subsequent SPECT/CT imaging confirmed the significantly increased accumulation in the known HCC manifestations (**Fig.3**). However, with QuiremScout® no dystopic accumulation in the gallbladder or elsewhere outside the liver was observed.

SIRT TREATMENT AND FOLLOW-UP

The following day, 6.7 GBq ¹⁶⁶Holmium-microspheres (QuiremSpheres®) were injected via catheter into the right hepatic artery without complications.

The distribution of QuiremSpheres® was almost identical to the distribution of QuiremScout® (**Fig.4**).

Ten weeks after the therapy, the HCC manifestations were constant to little regredient (**Fig.5**). The patient tolerated the SIRT procedure without any side effects. The liver function was still unchanged.

CONCLUSION

QuiremScout® is feasible and safe to use. The distribution of QuiremSpheres® was almost identical to the distribution of QuiremScout®.

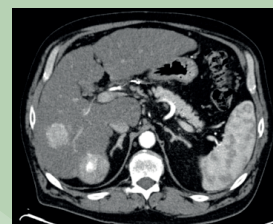


Fig 1. CT image before SIRT treatment

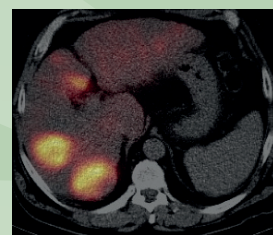


Fig 2. ^{99m}Tc-MAA SPECT/CT image

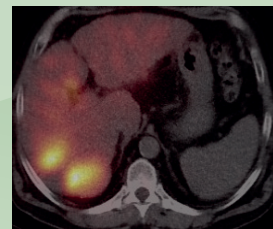

Fig 3. QuiremScout® SPECT/CT image

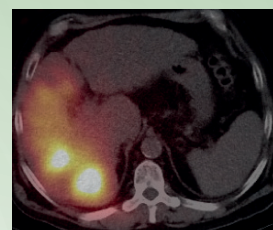


Fig 4. QuiremSpheres® SPECT/CT image

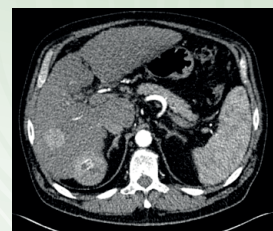


Fig 5. CT image after SIRT treatment (QuiremSpheres®)