

QuiemSpheres® treatment in 73-years old female HCC patient

QuiemScout® and Dual Isotope SPECT/CT technology enable pre-treatment evaluation HEPAR Primary Trial

Physician: Prof. dr. M.G.E.H Lam (NM), Dr. R.C.G. Bruijnen (IR), M.T.M. Reinders-Hut

Location: University Medical Center Utrecht, Utrecht, the Netherlands

PATIENT CLINICAL INFORMATION

A 73-years old female patient diagnosed with hepatocellular carcinoma (HCC) with liver only disease was treated with holmium-166 (¹⁶⁶Ho) SIRT. Patient presented with ECOG status 1, no signs of encephalopathy. Liver function analysis showed an increase in ALP and γ -GT levels as well as slightly elevated ASAT and ALAT levels, all grade 1. Bilirubin, INR and albumin level were normal; Child Pugh A5. Patient did not receive any relevant previous therapy.

PROCEDURE AND OUTCOME

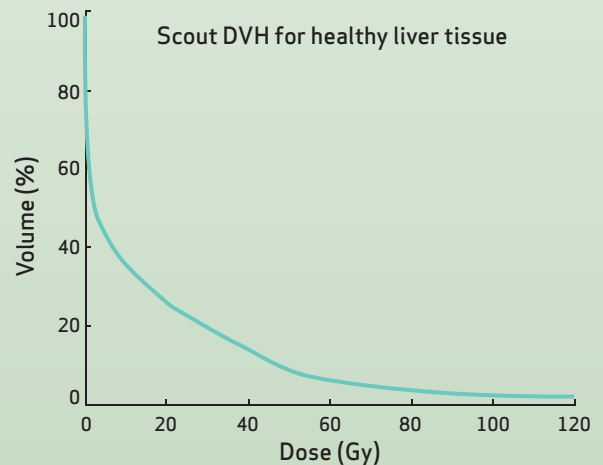
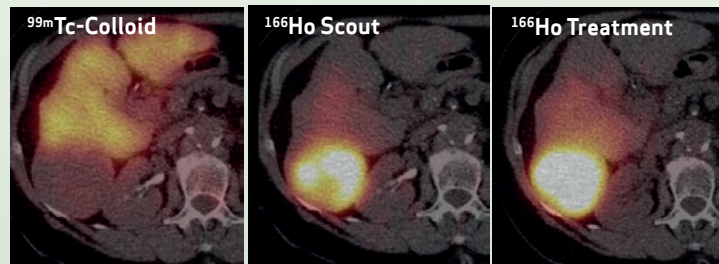
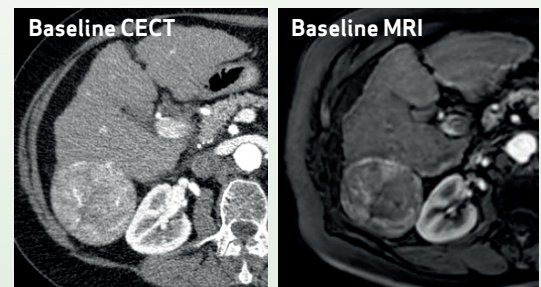
SIRT was approved by the multidisciplinary tumour board. The treatment strategy was a lobar approach via the right hepatic artery (RHA) to segments 5-8. An average perfused volume absorbed dose of 60 Gy was planned.

QuiemScout® (a test dose of 250 MBq ¹⁶⁶Ho microspheres) was administered via the RHA by transfemoral access. Following QuiemScout® administration, dual isotope SPECT/CT was performed, using the intra-arterial injected ¹⁶⁶Ho microspheres and technetium-99m (^{99m}Tc) colloid. Two distribution maps were created from the dual isotope SPECT/CT. A normal liver map based on the 140 keV energy window of ^{99m}Tc colloid, and a scout dose distribution map based on the 80 keV energy window of ¹⁶⁶Ho microspheres. A dose volume histogram (DVH) was constructed using the two maps to predict healthy tissue absorbed dose. Based on the DVH, which demonstrated that only 15% of healthy tissue receives a dose higher than 40 Gy, it was decided to treat the patient. No lung shunting or other extrahepatic activity was observed.

In a same day protocol, 4.5 GBq of QuiemSpheres® was injected via the RHA. The treatment procedure was well tolerated. No stasis or retrograde reflux were observed.

FOLLOW-UP

Post-treatment verification with SPECT/CT showed excellent distribution of the microspheres. Three months after the SIRT procedure, based on mRECIST, MR images showed reduction in size and enhancement of the target lesions. The large lesion in segment 6 was reduced from 71 mm diameter to 42 mm, showing a largely avascular tumor, with some enhancement on the edge.



DVH created by UMCU in-house developed software

